

# Electroconvulsive therapy-induced brain plasticity determines therapeutic outcome in mood disorders

Juergen Dukart<sup>a,b,1</sup>, Francesca Regen<sup>c,1</sup>, Ferath Kherif<sup>a</sup>, Michael Colla<sup>c,d</sup>, Malek Bajbouj<sup>c</sup>, Isabella Heuser<sup>c</sup>, Richard S. Frackowiak<sup>a</sup>, and Bogdan Draganski<sup>a,b,2</sup>

<sup>a</sup>Laboratoire de Recherche en Neuroimagerie, Département des Neurosciences Cliniques–Centre Hospitalier Universitaire Vaudois, Université de Lausanne, 1011 Lausanne, Switzerland; <sup>b</sup>Department of Neurology, Max-Planck Institute for Human Cognitive and Brain Sciences, 04103 Leipzig, Germany; <sup>c</sup>Experimental and Clinical Research Centre, Charité-University of Medicine Berlin, Campus Berlin Buch, 13125 Berlin, Germany; and <sup>d</sup>Department of Psychiatry and Psychotherapy, Charité-University of Medicine Berlin, Campus Benjamin Franklin, 14050 Berlin, Germany

Edited by Marcus E. Raichle, Washington University in St. Louis, St. Louis, MO, and approved December 11, 2013 (received for review November 14, 2013)

There remains much scientific, clinical, and ethical controversy concerning the use of electroconvulsive therapy (ECT) for psychiatric disorders stemming from a lack of information and knowledge about how such treatment might work, given its nonspecific and spatially unfocused nature. The mode of action of ECT has even been ascribed to a “barbaric” form of placebo effect. Here we show differential, highly specific, spatially distributed effects of ECT on regional brain structure in two populations: patients with unipolar or bipolar disorder. Unipolar and bipolar disorders respond differentially to ECT and the associated local brain-volume changes, which occur in areas previously associated with these diseases, correlate with symptom severity and the therapeutic effect. Our unique evidence shows that electrophysical therapeutic effects, although applied generally, take on regional significance through interactions with brain pathophysiology.

magnetic resonance imaging | voxel-based morphometry | unipolar depression | hippocampus

Electroconvulsive therapy (ECT) is the oldest well-established procedure for somatic treatment of unipolar and bipolar disorders (1); however, its precise mechanism of action is still unclear (2). Our current understanding is that the antidepressant effect of ECT is partially mediated by seizure-induced neurotrophic effects, resulting in increased rates of neurogenesis, synaptogenesis, and glial proliferation, particularly in the hippocampus (3–5). Modern neuroimaging experiments have shown a critical role for the subgenual cortex (Brodmann area 25) (6) and deep brain stimulation of this area also results in alleviation of symptoms (7, 8). Concerns regarding structural brain damage caused by ECT have been largely attenuated because of a lack of experimental evidence for ECT-induced neuronal damage (9). The scarce in vivo evidence for ECT-induced structural brain plasticity comes from region-of-interest (ROI) imaging studies reporting ECT-related hippocampal volume increases (10) that correlate with clinical outcome (11, 12). Limited by an ROI approach and a lack of adequate control groups, these studies may have incompletely detected the effects of right unilateral ECT and failed to distinguish them from pharmacologically induced changes or indeed the effects of disease.

We decided to resolve these ambiguities by carrying out a study with drug responsive (no-ECT) and drug-resistant (ECT) patients with either uni- or bipolar depression (Fig. 1 and Table 1). The two psychiatric conditions are considered separate from pathophysiological and nosological viewpoints. A group of normal volunteers was included to control for non-ECT-associated confounds and to provide a way of assessing ECT-associated therapeutic effects. All subjects were recruited and imaged using structural magnetic resonance at entry (time point 1, TP1). If unresponsive to drugs, patients had ECT administered unilaterally to the right hemisphere. All study participants were imaged again at 3 mo (TP2) and 6 mo (TP3). ECT was given at any time if there was evidence of resistance to treatment. We were

interested to see if there are any local anatomical effects attributable to ECT and whether any improvements of mood are explained by interaction between ECT and differentially distributed, disease-modified, brain regions.

## Results

Behaviorally, the patient groups were significantly different from controls at all time points on the Hamilton Depression Rating Scale (HDRS) (13). At TP2 and TP3 the ECT-treated and -untreated patients both had attenuated and similarly depressed mood as both were being optimally treated (Fig. 2A). Both patient groups improved symptomatically between TP1 and TP2 but no further improvement was noted at TP3 [ECT TP1 vs. T2:  $t(9) = 4.4$ ;  $P = 0.002$ ; no-ECT TP1 vs. TP2:  $t(23) = 5.3$ ;  $P < 0.001$ ; ECT TP2 vs. TP3:  $t(9) = 1.2$ ;  $P = 0.273$ ; no-ECT TP2 vs. TP3:  $t(23) = 0.9$ ;  $P = 0.375$ ].

The effect of ECT on brain anatomy in all patients was monitored using state-of-the-art, automated, voxel-based morphometry (14) on magnetic resonance brain data with imaging parameters optimized to provide maximal contrast between gray and white matter (15). The change of local gray matter volume (GMV) has been often discussed as a time-integrated effect necessary for a prolonged functional change. Analyses were carried out with a full factorial design matrix implemented in Statistical Parametric Mapping software ([www.fil.ion.ucl.ac.uk/spm](http://www.fil.ion.ucl.ac.uk/spm)) that included diagnosis and time as a between- and within-subject factor, respectively. ECT was entered as a binary covariate (yes/no), with the “yes” condition assigned if the patient

## Significance

**Electroconvulsive therapy is controversial: How does a major electrical discharge over half the brain result in recovery in disorders such as refractory major depression and manic depression, which are apparently different diseases? We find local but not general brain anatomy changes following electroconvulsive therapy that are differently distributed in each disease, and the areas affected are those implicated as abnormal in each disorder. An interaction between electroconvulsive therapy and specific pathology appears to be responsible for the therapeutic effect. Our results have implications for other electrically based brain treatments, such as deep brain stimulation and transcranial magnetic stimulation.**

Author contributions: J.D., F.R., F.K., M.C., M.B., I.H., R.S.F., and B.D. designed research; J.D., F.R., M.C., and M.B. performed research; F.K. contributed new reagents/analytic tools; J.D. analyzed data; and J.D., F.R., F.K., I.H., R.S.F., and B.D. wrote the paper.

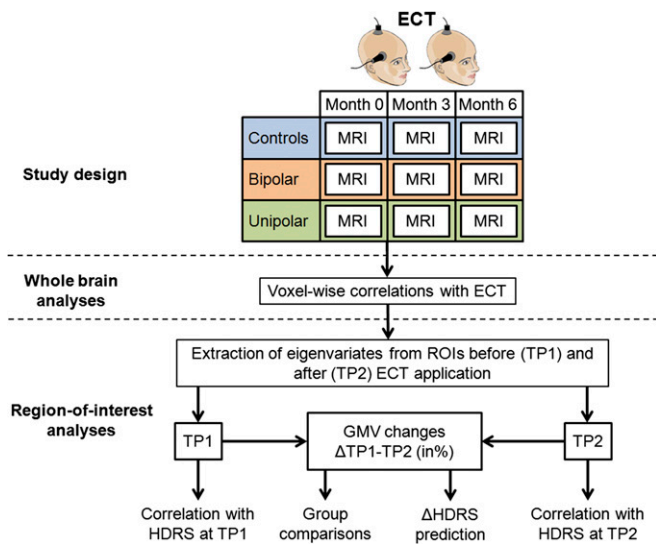
The authors declare no conflict of interest.

This article is a PNAS Direct Submission.

Freely available online through the PNAS open access option.

<sup>1</sup>J.D. and F.R. contributed equally to this work.

<sup>2</sup>To whom correspondence should be addressed. E-mail: bogdan.draganski@gmail.com.



**Fig. 1.** Schematic representation of study design and statistical analyses. ECT given at any time point if clinically indicated.

received ECT in a period preceding an MRI scan. All analyses were adjusted for age, sex, and total intracranial volume.

Right unilateral ECT was correlated with regional increases in local GMV only in the right hemisphere and restricted to: (i) the hippocampus, amygdala, and anterior temporal pole (this cluster is referred to as “hippocampal complex”); (ii) the insula; and (iii) the subgenual cortex (Brodmann area 25) (Fig. 2B). Local GMV decreases associated with ECT were noted in (iv) the right middle and inferior frontal cortex and premotor regions (referred to together as the “prefrontal cortex”). Except for the insula, these results are significant after adjustment for the effects of drug treatment. This analysis also revealed significant antidepressant drug effects associated with negative GMV correlation in the left entorhinal cortex, and for mood stabilizers a negative correlation with the right insula, right anterior middle frontal gyrus, and left dorsolateral prefrontal cortical GMV. These drug-implicated regions did not overlap with the brain anatomy network associated with ECT treatment, except in the anterior insula.

We then looked only at 3-mo time periods in which a first ECT session was administered, choosing suitable control periods in no-ECT patients and control subjects. We compared GMV changes extracted from regions of interest detected in the above correlational analyses (hippocampal complex, prefrontal and subgenual cortices) between ECT patients, no-ECT patients, and healthy controls. ANOVAs and subsequent post hoc *t* tests demonstrated significant between-group differences in all three regions [hippocampal complex:  $F(2,52) = 20.3$ ;  $P < 0.001$ ; subgenual cortex:  $F(2,52) = 6.7$ ;  $P = 0.002$ ; prefrontal cortex:  $F(2,52) = 6.0$ ;

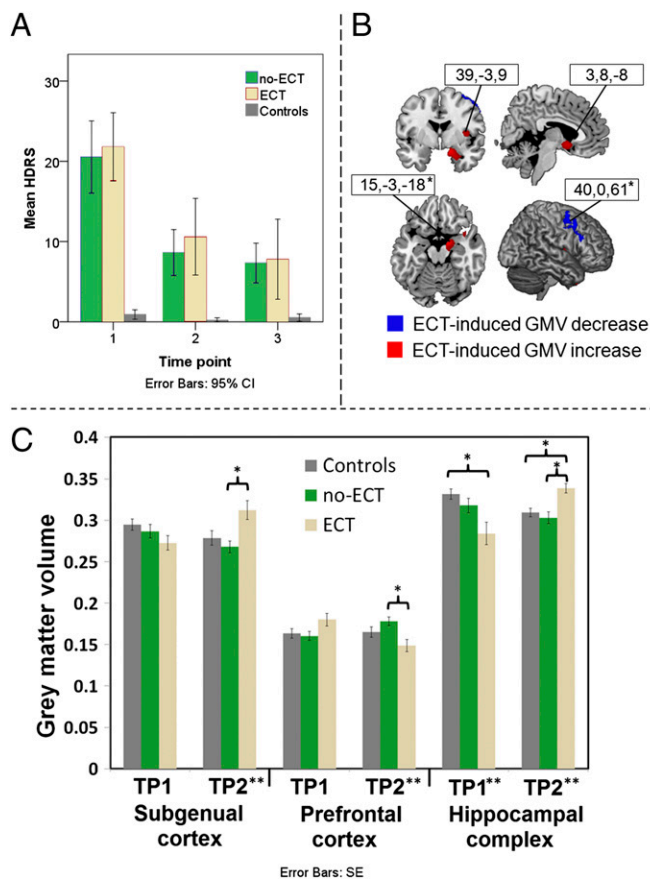
**Table 1. Subject group characteristics**

Characteristics	No-ECT ( <i>n</i> = 24)	ECT ( <i>n</i> = 10)	Controls ( <i>n</i> = 21)	Statistical test (test value, <i>df</i> , <i>P</i> )
Age (mean ± SD)	47.9 ± 11.1	53.9 ± 10.7	47.3 ± 9.6	ANOVA (1.4, 2, 0.244)
Sex (male/female)	11/13	4/6	8/13	$\chi^2(0.3, 2, 0.864)$
Diagnosis (unipolar/bipolar, <i>n</i> )	14/10	5/5	—	Fisher's exact ( $P = 0.718$ )
HDRS (mean ± SD)	20.5 ± 10.7	21.8 ± 5.9	0.9 ± 1.3	ANOVA (45.7, 2, <0.001)
YMRS (mean ± SD) <sup>†</sup>	21.6 ± 7.8	25.0*	—	Wilcoxon (0.3536, 0.7237)
Age at onset (y, mean ± SD)	38.0 ± 12.0	35.7 ± 10.6	—	ANOVA (0.247, 1, 0.6041)
Duration of current depressive episode (mo)	3.3 ± 3.3	7.0 ± 7.0	—	ANOVA (4.541, 1, 0.041)
Duration of current manic episode (mo) <sup>†</sup>	0.2 ± 0.5	0.6 ± 1.9	—	ANOVA (1.198, 1, 0.282)
Total number of depressive episodes	3.7 ± 2.5	11.3 ± 10.5	—	ANOVA (7.099, 1, 0.012)
Total number of manic episodes	1.8 ± 4.2	3.1 ± 4.5	—	ANOVA (0.663, 1, 0.421)
Total lifetime duration of depression (mo)	17.1 ± 12.5	42.7 ± 37.2	—	ANOVA (9.203, 1, 0.005)
Total lifetime duration of mania/ mixed state (mo)	5.4 ± 14.8	7.1 ± 9.8	—	ANOVA (0.108, 1, 0.7446)
Cumulative time treated with antidepressants (y)	3.3 ± 6.1	8.2 ± 9.4	—	ANOVA (1.435, 1, 0.239)
Cumulative time treated with lithium (y)	2.2 ± 8.2	2.5 ± 4.0	—	ANOVA (0.006, 1, 0.939)
Number of hospitalizations	3.4 ± 6.8	7.1 ± 5.1	—	ANOVA (24.74, 1, 0.00)
Antidepressants (%)				
TP1	75	90	—	Fisher's exact (0.250, $P = 0.645$ )
TP2	75	80	—	Fisher's exact (0.334, $P = 1.0$ )
TP3	83.3	90	—	Fisher's exact (0.382, $P = 1.0$ )
Lithium (%)				
TP1	4.17	20.0	—	Fisher's exact (0.181, $P = 0.201$ )
TP2	16.67	20.0	—	Fisher's exact (0.356, $P = 1.0$ )
TP3	16.67	20.0	—	Fisher's exact (0.356, $P = 1.0$ )
Mood stabilizer (%)				
TP1	29.17	40	—	Fisher's exact (0.254, $P = 0.692$ )
TP2	33.33	40	—	Fisher's exact (0.282, $P = 0.714$ )
TP3	33.33	40	—	Fisher's exact (0.282, $P = 0.714$ )
Atypical antipsychotics (%)				
TP1	33.3	90.0	—	Fisher's exact (0.003, $P = 0.006$ )
TP2	50.0	80.0	—	Fisher's exact (0.087, $P = 0.141$ )
TP3	41.67	90.0	—	Fisher's exact (0.011, $P = 0.020$ )

Clinical and demographic characteristics of patients with ECT, receiving only drug treatment (no-ECT) and control subjects. ANOVA (variance-weighted or log-transformed if appropriate); tests with significant between-group differences are indicated in bold. %, Percentage of patients receiving this drug treatment within the entire study period.

\*Only for one patient.

<sup>†</sup>Only for bipolar patients in their manic episode.



**Fig. 2.** Imaging and behavioral results. (A) Plot of mean HDRS scores for all time points. (B) Results of voxel-based morphometry analyses showing ECT-induced increases and decreases in GMV. For representation purposes, results are displayed at significance threshold of  $P < 0.001$  uncorrected at voxel level and a cluster extent threshold of 200 voxels. Coordinates corresponding to Montreal Neurological Institute standard space. CI, confidence interval; an asterisk represents significant at a cluster extent threshold of  $P < 0.05$  family-wise error corrected for multiple comparisons and adjusted for nonstationarity of smoothness (28). (C) Mean GMV at baseline and after treatment displayed for ECT, no-ECT patients, and control subjects (first two time points). \*\*Significant difference between the groups in an ANOVA; \*significant difference in a post hoc  $t$  test ( $P < 0.05$ , two-tailed, Bonferroni corrected for multiple comparisons); SE, SE of mean; ECT, patients with electroconvulsive therapy; no-ECT, patients receiving only drug treatment.

$P = 0.004$ ] (Fig. 3A). This result is strong evidence of a differential primary main effect of ECT on brain structures. We tested for GMV changes between the three groups before and after ECT using ANOVAs and post hoc  $t$  tests. We demonstrate significantly higher GMV in the subgenual cortex and hippocampal complex that is paralleled by prefrontal cortex GMV decreases after ECT in the ECT group compared with no-ECT patients (Fig. 2C). Before ECT, ECT patients had significantly lower GMV compared with control subjects in the hippocampal complex.

We used an analysis of covariance (ANCOVA) with diagnosis, ECT, and GMV changes to predict symptomatic improvement as an independent measure in patients. Diagnosis [unipolar vs. bipolar:  $F(14,33) = 7.6$ ;  $P = 0.012$ ], GMV changes in subgenual cortex [ $F(14,33) = 7.4$ ;  $P = 0.014$ ], and hippocampal complex [ $F(14,33) = 13.5$ ;  $P = 0.002$ ] were all significant predictors of improved HDRS scores after ECT. Furthermore, we identified significant two-way interactions between ECT and hippocampal GMV changes [ $F(14,33) = 4.7$ ;  $P = 0.044$ ], between diagnosis and hippocampal complex GMV changes [ $F(14,33) = 6.8$ ;  $P = 0.018$ ], and between diagnosis and subgenual cortex GMV

changes [ $F(14,33) = 4.8$ ;  $P = 0.041$ ], with all being significant predictors of symptom alleviation. Finally, we identified two significant three-way interactions between ECT, diagnosis, and both the subgenual cortex [ $F(14,33) = 10.3$ ;  $P = 0.005$ ] and hippocampal complex [ $F(14,33) = 5.8$ ;  $P = 0.026$ ] GMV changes. Overall, this ANCOVA explained 76.5% of the variance observed in clinical measures of symptomatic improvement.

These three-way interactions originate from specific correlations between the examined variables. To illustrate these variables, we performed correlation analyses between symptomatic improvement and GMV changes subdivided by diagnosis and ECT treatment (Fig. 3B). In unipolar patients, ECT reverses the relationship between symptomatic improvement and subgenual GMV changes. In bipolar patients, the same effect of ECT is seen in the hippocampal complex. In a more static analysis we plotted the correlation strength between GMV and HDRS scores before ECT and then again for the first time point after ECT (Fig. 3C). This analysis shows that subgenual GMV is correlated with symptom severity in both uni- and bipolar patients before ECT but the correlation is disrupted after it. In the hippocampal complex, this effect is only observed in unipolar patients.

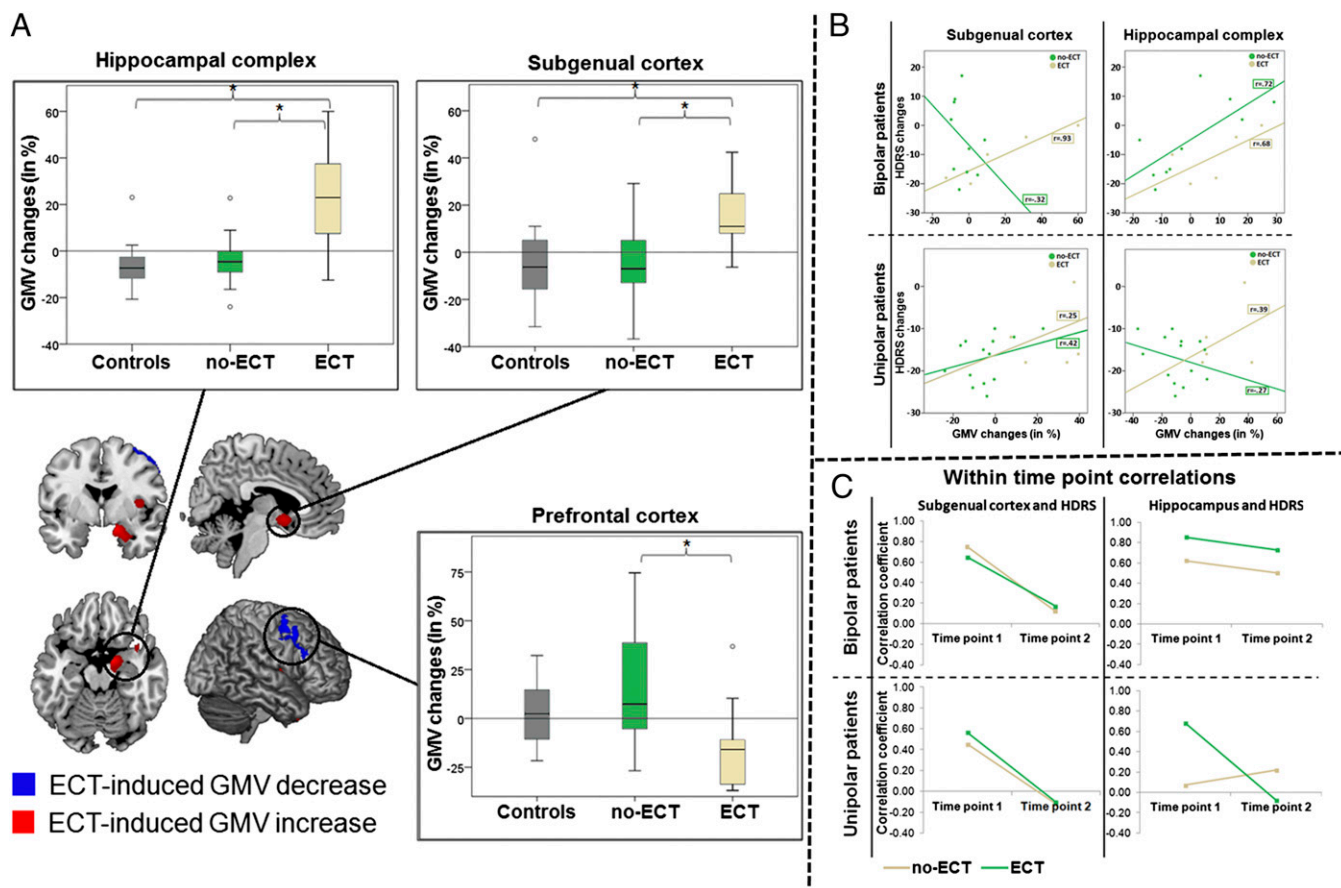
ECT dosage did not correlate significantly with GMV or HDRS changes (all  $P > 0.1$ ).

## Discussion

We demonstrate specific, bidirectional, locally distributed, brain plasticity effects of ECT and link these to clinical outcome in two debilitating psychiatric conditions. We believe that these results provide a clearer, although more complex, mechanistic, biologically motivated account of the treatment potential of ECT in other patient populations. The findings suggest that more focused electrical or magnetic adjuvant therapy associated with standard pharmacotherapy may be the way to go in future treatment development (2, 16, 17).

The anatomical distribution of ECT-associated GMV changes clarifies and extends findings from previous studies (3, 4, 11, 12), showing spatial effects on GMV in a theoretically estimated space affected by electric field propagation in the brain from unilateral ECT (18). Our result confirms the spatial distribution of the ECT effect in that regions subjected to the highest electric field strengths show the most structural change. The demonstrated anatomical pattern of local GMV changes largely overlaps the findings of ECT-induced decreases in serotonin receptor binding (19). However, our ECT patient cohort shows a prefrontal cortical GMV decrease in comparison with no-ECT patients, yet not to controls. Patients not receiving ECT showed disease-related GMV increases in the same area, suggesting a complex interaction between ECT, pathological mechanisms, and pharmacological treatment. The failure of previous studies to detect ECT-induced brain volume loss is explained by the lack of a no-ECT, pharmacotherapy-only control group (20). The observation of an initially lowered GMV in the hippocampal complex in ECT patients and its increase to a level comparable to the one observed in control subjects at recruitment, paralleled by improvement in depressive symptoms, supports the assumption of a treatment effect that is associated with—and perhaps mediated by—structural changes.

The three-way interactions between ECT, diagnosis, and brain structure clarify the response to ECT in the combined patient cohort, which is because of a differential ECT effect in unipolar depression and bipolar disorder. Given greater and also inverted correlations in the ECT compared with the no-ECT groups, our results suggest a reversal of the relationship between hippocampal complex GMV changes and severity of depressive symptoms in bipolar disease. We also identify an identical effect in unipolar depressed patients in the subgenual cortex, which is a target of choice for treatment of this disease by deep brain stimulation (7). The regions detected are consistent with an



**Fig. 3.** Results of post hoc analyses. (A) Plots of the mean hippocampal, prefrontal, and subgenual GMV, changes (in percent) induced by ECT treatment compared with no-ECT patients and control subjects. (B) Correlation coefficients obtained between changes in subgenual (Left) and hippocampal (Right) GMV, and changes in the HDRS. Results are displayed separately for bipolar and unipolar depression patients subdivided by treatment condition (ECT vs. no-ECT). (C) Correlation coefficients between HDRS scores and subgenual (Left) and hippocampal (Right) GMV and the time point before and after ECT treatment, choosing suitable control periods in no-ECT patients. Results are displayed separately for bipolar (Upper) and unipolar (Lower) depression patients subdivided by treatment condition. An asterisk represents significant difference between the groups at a threshold of  $P < 0.05$  (two-tailed, Bonferroni corrected).

anatomical network implicated in an emerging “hyperconnectivity hypothesis,” which proposes increased connectivity between these regions in depression (21) followed by a decrease after effective ECT (22).

A positive correlation between changes in both HDRS and GMV appears paradoxical, especially as the effect of ECT is to increase GMV in the same regions. This finding is explained by the fact that effective ECT and drug treatment appear to disrupt the link between symptom severity and GMV in the corresponding regions. Thus, an ECT-associated increase in local GMV is compatible with a therapeutic effect. Additionally, bipolar patients who show large GMV changes in response to ECT profit less from this therapy.

Voxel-based morphometry is a well-established technique with high sensitivity for subtle changes of regional brain anatomy (23). The anatomical basis of local GMV changes remains unclear, even at a mesoscopic level of measurement. Contributory factors may include water content and partitioning among tissue compartments, blood volume changes, local cell swelling, synaptic proliferation, changes in cell body sizes, changes in perfusion, and the like. Notwithstanding, the effects are clearly biological and distributed; they predict complex behavior and therapy effects, as demonstrated many times in the past in other conditions as well as in this study (24).

Several limitations should be considered in the interpretation of our findings. First, the ECT and no-ECT groups differ

significantly with respect to duration of current depressive episode, total number of depressive episodes, cumulative time spent in depression, and lifetime exposure to different drugs. Given that ECT was only administered to treatment-resistant patients and that all of these significant factors have been previously associated with increased resistance to treatment (25), our findings are not unexpected and may have contributed to differential changes observed in the ECT cohort. Second, given the small number of patients receiving ECT, especially when these are subdivided by diagnosis, our demonstration of differential ECT effects in uni- and bipolar patients should be considered exploratory and subject to validation in bigger ECT cohorts. Similarly, for observed regional correlations with ECT only the hippocampal and the prefrontal cluster survive the more conservative statistical threshold associated with correction for multiple comparisons. Therefore, our findings in the subgenual cortex require validation in future studies. The small group sizes prevented formal testing of whether the differential ECT effects indicate a reversal or simply abolition of the correlation between HDRS and GMV changes we find. Finally, we did not observe significant correlations between ECT dosage and HDRS and GMV changes. A further reason, beside the low power of our study, may be a differential and unknown contribution of two factors determining interindividual differences in received ECT dosage, namely individually determined seizure thresholds and clinically indicated continuation of ECT in nonresponders. Future research, using more

focused brain-stimulation techniques (16), is needed to define biologically based therapeutic indications in other similar common disorders. The interaction of ECT with endogenous mechanisms to modulate regional cortical volume could also provide new ways of investigating adult human brain plasticity.

## Methods

**Subjects.** We recruited patients with unipolar depression ( $n = 19$ ), bipolar disorder ( $n = 15$ ), and healthy control subjects ( $n = 21$ ), who were scanned at three different time points, each 3-mo apart (Table 1). All patients were ECT-naïve at TP1. Psychiatric diagnoses were made on the basis of *Diagnostic and Statistical Manual of Mental Disorders-IV* criteria. All patients underwent an extensive clinical evaluation at each time point. Drug treatment (antidepressants, lithium, mood stabilizers, atypical antipsychotics) was prescribed as indicated by psychiatric evaluation. Patients with depression showing resistance to drug treatment (five bipolar and five unipolar) additionally underwent ECT, either in the period between TP1 and TP2 (two patients), between TP2 and TP3 (one patient), or in both time periods (seven patients). By this assignment, 10 patients received ECT treatment and the other 24 patients were considered a control group (no-ECT).

Right-sided unilateral ECT was administered three times a week using a square-wave, brief-pulse, constant-current device. Seizure threshold was individually determined by the administration of repeated stimuli of increasing intensity until a generalized seizure occurred; stimulus intensity was set at 2.5-times seizure threshold. The intensity was further elevated if there was an absence of seizures or their intensity was clinically judged inadequate. Nine sessions of ECT were given and if inadequate in terms of symptom relief, continued until a response was achieved. If clinically indicated, patients received maintenance ECT. The average cumulative ECT dosage in the study period was 5430.6 millicoulombs (mC) (SD: 2930.7 mC).

There were no significant differences between treated and untreated patient groups in terms of age, sex, and symptom severity. Symptom severity was evaluated using the HDRS (13). The Young Mania Rating Scale (YMRS) (26) was used only for bipolar patients with a manic or mixed episode. At the first time point four bipolar patients showed manic symptoms, whereas all of the other patients were in a depressive episode. Changes in HDRS scores across time in the ECT and no-ECT groups were analyzed using paired  $t$  tests ( $P < 0.05$ , two-tailed) implemented in SPSS 20 ([www.spss.com/statistics](http://www.spss.com/statistics)). Additionally, HDRS scores in these subjects and normal controls were compared with each other over time using a one-way ANOVA design ( $P < 0.05$ , with additional post hoc pairwise  $t$  tests ( $P < 0.05$  two-tailed) if an ANOVA revealed significant between group differences).

This study was approved by the local ethics committee and was carried out in accordance with the latest version of the Declaration of Helsinki. All participants gave written informed consent before participation in the study; healthy subjects were paid for their participation.

**Structural MRI.** Structural MRI scans were acquired on a 1.5T Magnetom VISION (Siemens) equipped with a standard circularly polarized head coil. A vacuum-molded head holder (Vac-PacTM, Olympic Medical) was used to reduce motion of the subject's head. All data were acquired in sagittal mode using a 3D T1-weighted magnetization prepared rapid gradient echo (MPRAGE) sequence (TR = 11.4 ms, TE = 4.4 ms, field of view = 269 mm, flip angle = 30°, slice thickness = 1.05 mm, 154 contiguous slices, pixel: 1.05 × 1.05 mm<sup>2</sup>, slab 161 mm, matrix size = 256 × 256).

**Image Preprocessing.** All image preprocessing steps were carried out using the SPM8 software package (Statistical Parametric Mapping software: [www.fil.ion.ucl.ac.uk/spm](http://www.fil.ion.ucl.ac.uk/spm)) implemented in Matlab 7.11 (MathWorks). Preprocessing consisted of within-subject midway coregistration to account for between-session variance (27), automated tissue classification, and spatial registration followed by scaling with the Jacobian determinants to preserve the total amount of signal. For optimal spatial registration we additionally used the Diffeomorphic Anatomical Registration using Exponentiated Lie algebra (DARTEL) approach (14), building a study-specific template created from all subjects at all time points. Maps of GMV were smoothed with a Gaussian kernel of 8-mm full-width-at-half-maximum.

**Statistical Analysis of Imaging Data.** Statistical analyses of whole-brain imaging data were calculated in the SPM8 software package ([www.fil.ion.ucl.ac.uk/spm](http://www.fil.ion.ucl.ac.uk/spm)) implemented in Matlab R2011b (MathWorks). All region of interest analyses were performed using the SPSS 20 software package ([www.spss.com/statistics](http://www.spss.com/statistics)). An overview of all performed statistical analyses is given in Fig. 1D.

**Whole-Brain Analysis.** To investigate ECT-related structural changes we created a fully factorial design matrix with the factors DIAGNOSIS and TIME, where diagnosis is a between- and time a within-subject factor. Given that each patient underwent ECT based solely on clinical criteria, in some patients ECT was given between TP1 and TP2, in others between TP2 and TP3. To account for this difference, ECT was entered as a binary covariate (yes/no) into the model with the "yes" condition assigned if a patient received ECT in 3 mo immediately preceding an MRI scan. To exclude a possible coincidence of ECT with a specific drug-treatment regimen, we computed a second fully factorial design with the inclusion of drug treatment (antidepressants, lithium, mood stabilizer, atypical antipsychotics) in the form of additional binary variables. In this second analysis we evaluated the potential effects of contemporary exposure to different drug treatments on ECT-associated structural brain changes. In all design matrices age, sex, and total intracranial volume were included as covariates to control for their effects. Results were evaluated at  $P < 0.001$  uncorrected at voxel level with an extent threshold of 200 consecutive voxels to reduce false-positives (28). Additionally, all results were evaluated at a more conservative threshold of  $P < 0.05$  with family-wise error, corrected for multiple comparisons, and adjusted for nonstationarity of smoothness in voxel-based morphometry data (29).

**ROI Analysis.** We investigate the effects of ECT using whole-brain, fully factorial analyses to detect brain regions that are modulated by ECT treatment. However, these do not provide a statistical measure of how ECT effects differ from GMV changes in the same regions in both control groups (no-ECT and healthy controls). To enable a more detailed understanding of the relationships observed in the fully factorial analyses, we performed post hoc ROI analyses of all regions (hippocampal complex, subgenual, and prefrontal cortex) that showed a correlation with ECT when controlling for drug-treatment effects. For each patient receiving ECT we first calculated the corresponding relative GMV changes [in percent, computed as  $100 \times (\text{GMV}_{\text{post}} - \text{GMV}_{\text{pre}}) / \text{GMV}_{\text{pre}}$ ] between the last time point before ECT treatment (GMV<sub>pre</sub>) and the first time point after initiation of ECT (GMV<sub>post</sub>) based on eigenvariables of clusters showing ECT-related volume changes. In no-ECT patients and control subjects, the first and second scanning time points were used to calculate equivalent GMV changes. In a second step, we compared these changes between control, ECT, and no-ECT groups using a one-way ANOVA design. Furthermore, to evaluate potential differences between the three groups in GMV at baseline and after ECT, we additionally computed ANOVAs comparing GMV<sub>pre</sub> and GMV<sub>post</sub>. If an ANOVA revealed significant differences ( $P < 0.05$ ) post hoc  $t$  tests ( $P < 0.05$ , two-tailed, Bonferroni-corrected) were calculated to evaluate pairwise between-group differences.

To investigate how changes in detected regions modulate changes in HDRS scores we computed an ANCOVA (significance threshold:  $P < 0.05$ ) with factors DIAGNOSIS (bipolar/unipolar) and ECT (yes/no). Percent GMV changes (calculated from ANOVAs) in hippocampal complex, and subgenual and prefrontal cortices were included as covariates and changes in HDRS (HDRS difference between the same time points as used for computation of GMV changes: HDRS<sub>2</sub> – HDRS<sub>1</sub>) were used as dependent variables. Factor DIAGNOSIS was included because both diseases are considered to be separate nosological entities, and therefore different mechanisms could potentially determine symptom severity. In this design, we modeled all main effects (of which there were five), all possible two-way interactions between both DIAGNOSIS and ECT and changes in the three ROIs (six two-way interactions, e.g., DIAGNOSIS/prefrontal or ECT/prefrontal), and all possible three-way interactions between DIAGNOSIS, ECT, and each of the regions separately (e.g., ECT/DIAGNOSIS/prefrontal). To illustrate significant three-way interactions we computed Pearson correlation coefficients between changes in HDRS and GMV and between HDRS scores and GMV before and after ECT subdivided by DIAGNOSIS and treatment condition. Additionally, to evaluate if ECT dosage is related to HDRS and GMV changes in the three regions detected in whole-brain analyses, we computed Pearson correlation coefficients between these variables. These correlations with ECT dosage were evaluated at a two-tailed threshold of  $P < 0.05$ .

**ACKNOWLEDGMENTS.** B.D. is supported by the Swiss National Science Foundation (National Center for Competence in Research Synapsy, Project Grant 320030\_135679 and Sonderprogramm Universitaetsmedizin 33CM30\_140332/1), Foundation Parkinson Switzerland, Foundation Synapsy, Novartis Foundation for Medical-Biological Research, and Deutsche Forschungsgemeinschaft (Kfo 247).

- Weiner RD, Falcone G (2011) Electroconvulsive therapy: How effective is it? *J Am Psychiatr Nurses Assoc* 17(3):217–218.
- Hoy KE, Fitzgerald PB (2010) Brain stimulation in psychiatry and its effects on cognition. *Nat Rev Neurol* 6(5):267–275.
- Wennström M, Hellsten J, Tingström A (2004) Electroconvulsive seizures induce proliferation of NG2-expressing glial cells in adult rat amygdala. *Biol Psychiatry* 55(5):464–471.
- Hellsten J, et al. (2002) Electroconvulsive seizures increase hippocampal neurogenesis after chronic corticosterone treatment. *Eur J Neurosci* 16(2):283–290.
- Chen F, Madsen TM, Wegener G, Nyengaard JR (2009) Repeated electroconvulsive seizures increase the total number of synapses in adult male rat hippocampus. *Eur Neuropsychopharmacol* 19(5):329–338.
- Drevets WC, Savitz J, Trimble M (2008) The subgenual anterior cingulate cortex in mood disorders. *CNS Spectr* 13(8):663–681.
- Johansen-Berg H, et al. (2008) Anatomical connectivity of the subgenual cingulate region targeted with deep brain stimulation for treatment-resistant depression. *Cereb Cortex* 18(6):1374–1383.
- Holtzheimer PE, et al. (2012) Subcallosal cingulate deep brain stimulation for treatment-resistant unipolar and bipolar depression. *Arch Gen Psychiatry* 69(2):150–158.
- Devanand DP, Dwork AJ, Hutchinson ER, Bolwig TG, Sackeim HA (1994) Does ECT alter brain structure? *Am J Psychiatry* 151(7):957–970.
- Nordanskog P, et al. (2010) Increase in hippocampal volume after electroconvulsive therapy in patients with depression: A volumetric magnetic resonance imaging study. *J ECT* 26(1):62–67.
- Lekwauwa R, McQuoid D, Steffens DC (2006) Hippocampal volume is associated with physician-reported acute cognitive deficits after electroconvulsive therapy. *J Geriatr Psychiatry Neurol* 19(1):21–25.
- Lekwauwa RE, McQuoid DR, Steffens DC (2005) Hippocampal volume as a predictor of short-term ECT outcomes in older patients with depression. *Am J Geriatr Psychiatry* 13(10):910–913.
- Hamilton M (1960) A rating scale for depression. *J Neurol Neurosurg Psychiatry* 23:56–62.
- Ashburner J (2007) A fast diffeomorphic image registration algorithm. *Neuroimage* 38(1):95–113.
- Deichmann R, Good CD, Josephs O, Ashburner J, Turner R (2000) Optimization of 3-D MP-RAGE sequences for structural brain imaging. *Neuroimage* 12(1):112–127.
- Edwards D, et al. (2013) Physiological and modeling evidence for focal transcranial electrical brain stimulation in humans: A basis for high-definition tDCS. *Neuroimage* 74:266–275.
- Berlim MT, Van den Eynde F, Daskalakis ZJ (2013) Efficacy and acceptability of high frequency repetitive transcranial magnetic stimulation (rTMS) versus electroconvulsive therapy (ECT) for major depression: A systematic review and meta-analysis of randomized trials. *Depress Anxiety* 30(7):614–623.
- Lee WH, et al. (2012) Regional electric field induced by electroconvulsive therapy in a realistic finite element head model: Influence of white matter anisotropic conductivity. *Neuroimage* 59(3):2110–2123.
- Langzenberger R, et al. (2013) Global decrease of serotonin-1A receptor binding after electroconvulsive therapy in major depression measured by PET. *Mol Psychiatry* 18(1):93–100.
- Coffey CE, et al. (1991) Brain anatomic effects of electroconvulsive therapy. A prospective magnetic resonance imaging study. *Arch Gen Psychiatry* 48(11):1013–1021.
- Sheline YI, Price JL, Yan Z, Mintun MA (2010) Resting-state functional MRI in depression unmasks increased connectivity between networks via the dorsal nexus. *Proc Natl Acad Sci USA* 107(24):11020–11025.
- Perrin JS, et al. (2012) Electroconvulsive therapy reduces frontal cortical connectivity in severe depressive disorder. *Proc Natl Acad Sci USA* 109(14):5464–5468.
- Ashburner J (2009) Computational anatomy with the SPM software. *Magn Reson Imaging* 27(8):1163–1174.
- Kanai R, Rees G (2011) The structural basis of inter-individual differences in human behaviour and cognition. *Nat Rev Neurosci* 12(4):231–242.
- Fava M, Davidson KG (1996) Definition and epidemiology of treatment-resistant depression. *Psychiatr Clin North Am* 19(2):179–200.
- Young RC, Biggs JT, Ziegler VE, Meyer DA (1978) A rating scale for mania: Reliability, validity and sensitivity. *Br J Psychiatry* 133:429–435.
- Thomas AG, et al. (2009) Functional but not structural changes associated with learning: An exploration of longitudinal voxel-based morphometry (VBM). *Neuroimage* 48(1):117–125.
- Wilke M, Kowatch RA, DelBello MP, Mills NP, Holland SK (2004) Voxel-based morphometry in adolescents with bipolar disorder: First results. *Psychiatry Res* 131(1):57–69.
- Hayasaka S, Phan KL, Liberzon I, Worsley KJ, Nichols TE (2004) Nonstationary cluster-size inference with random field and permutation methods. *Neuroimage* 22(2):676–687.